Anatómia kardiovaskulárneho systému

Systema circulatorium

Anatómia srdca

- Uložené medzi pľúcami
- Položené na bránici
- Aorta – medzi 1. a 2. rebrom vľavo

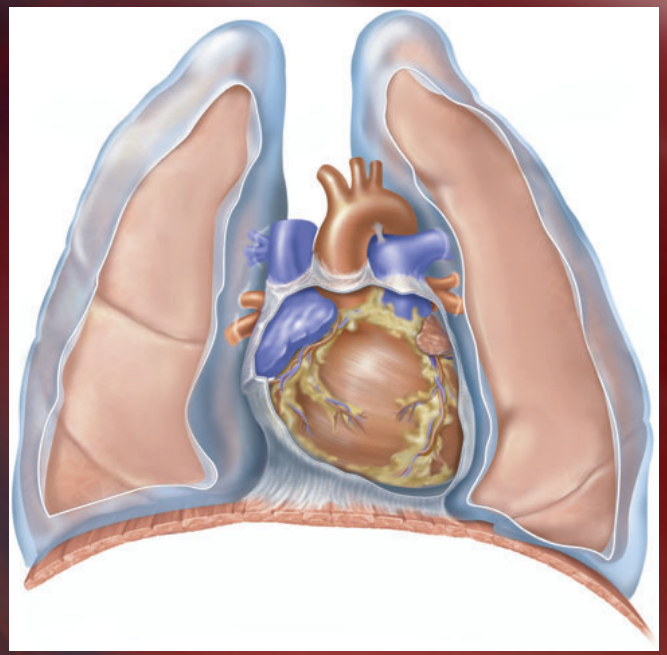

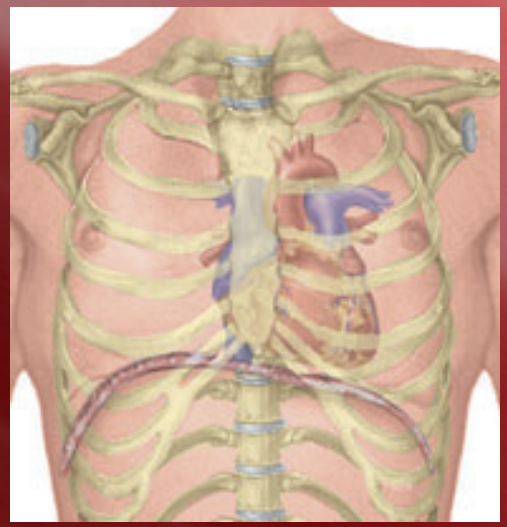

Anatómia srdca

- Uložené v obale – perikard
  - 2 vrstvy – medzi nimi perikardiálna tekutina (5-30 ml)
- 3 vrstvy svaloviny:
  - Epikard
  - Myokard
  - Endokard

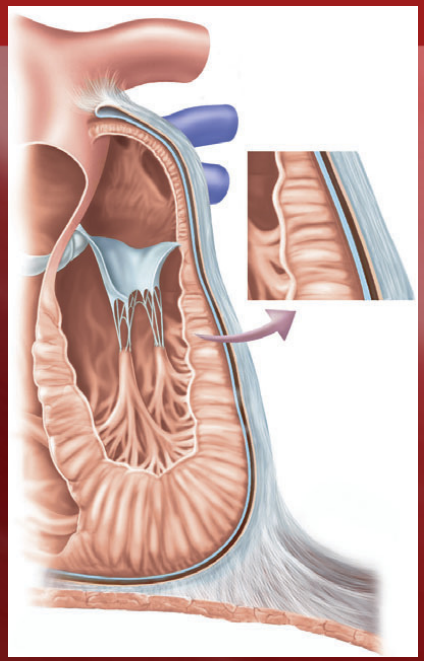

Anatómia srdca

- 2x predsieň (atrium) + 2x komora (ventriculus)
  - Ľavá str. = okysličená krv
  - Pravá str. = neokysličená k.
- Chlopne
  - Atrioventrikulárne
    - 2-cípa (vľavo)
    - 3-cípa (vpravo)
  - Semilunárne
    - Aorta
    - Pľúcna tepna

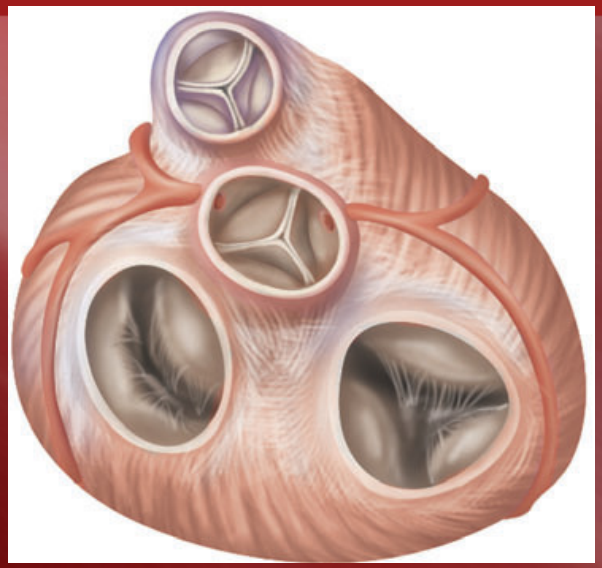

Anatómia srdca

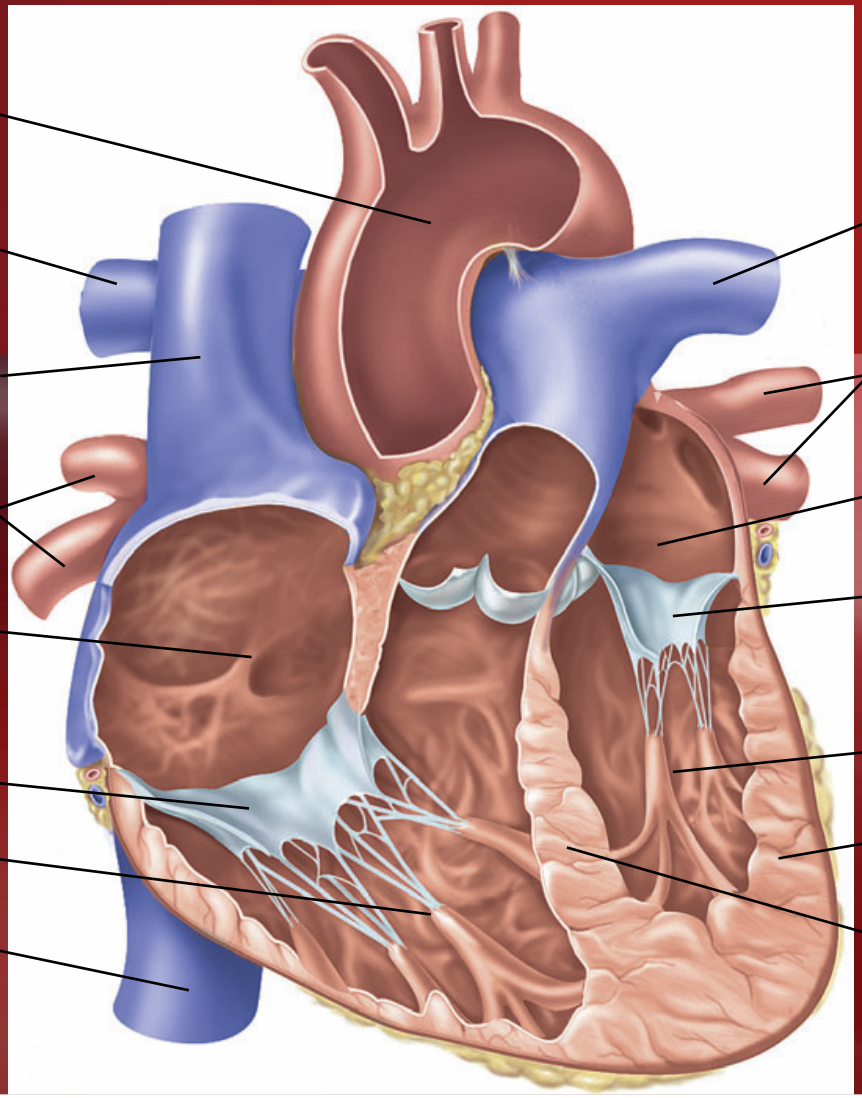

Anatómia srdca

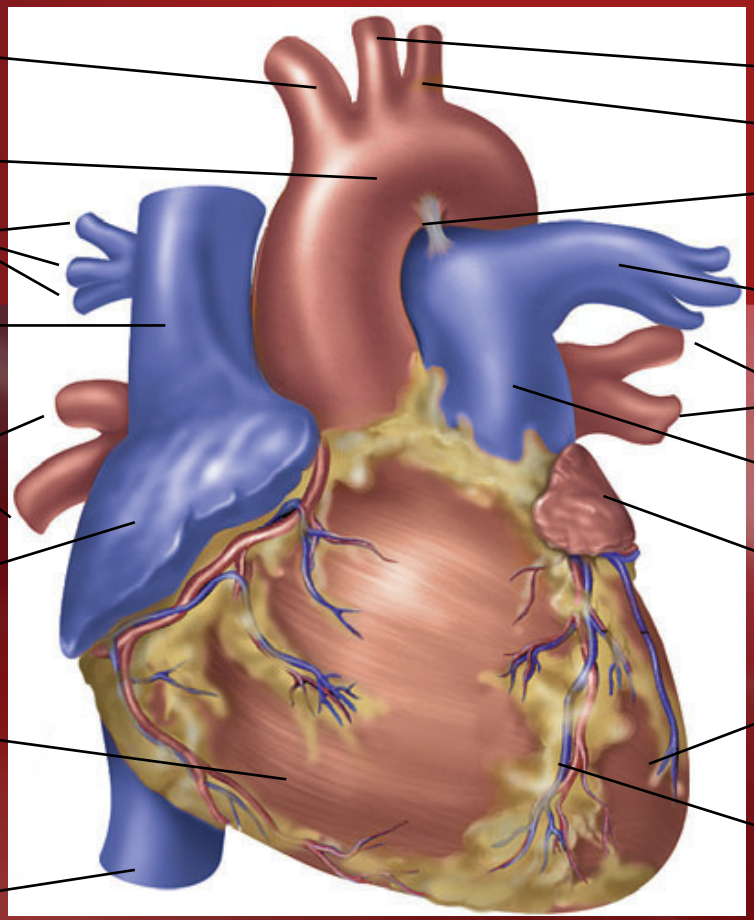

Anatómia srdca

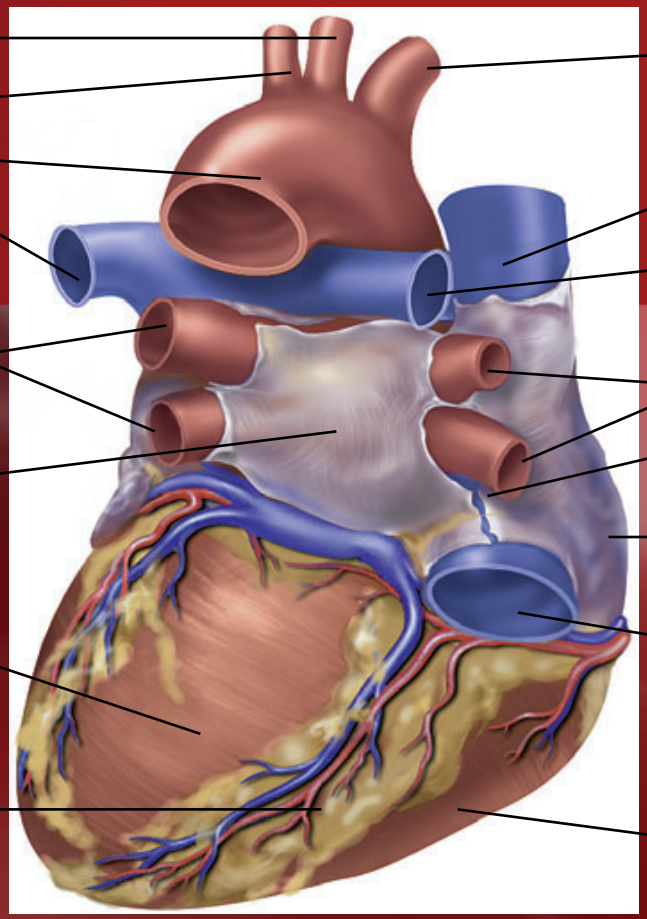

Ľ. krkavica
Ľ. podkľúčna tepna
Aorta
Ľ. pľúcna tepna
Ľ. pľúcne žily
Ľ. predsieň
Ľ. komora
Interventrikulárny sulcus

Hlavo-ramenný kmeň
Horná dutá žila
P. pľúcna tepna
P. pľúcne žily
P. predsieň
Dolná dutá žila
P. komora

Anatómia srdca

- Koronárne cievy
  - Zásobovanie srdca
  - Upchanie = infarkt

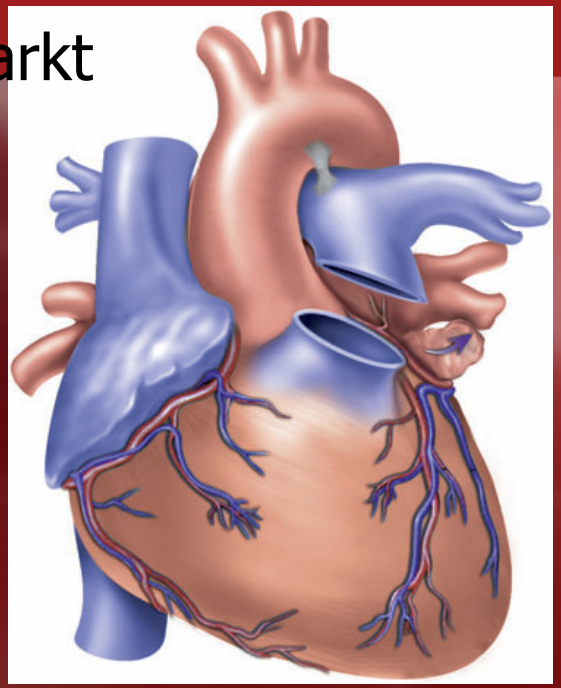

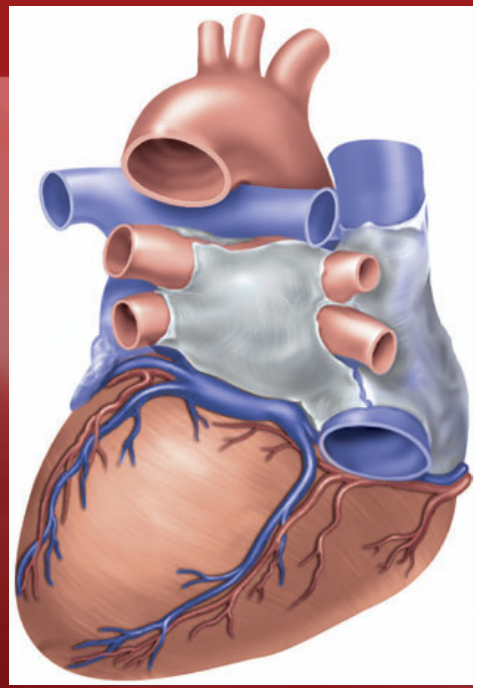

Cievy

- Tepny = arteriae
  - Tunica intima
    - Endotel
    - Elastická vrstva
  - Tunica media
    - hladká svalovina + kolagén
    - Elastická vrstva
      - Dôležitá pri premene nárazových výtokov krvi zo srdca na kontinuálny prúd
  - Tunica externa
    - Vasa vasorum – drobné cievy vyživujúce stenu cievy

Cievy

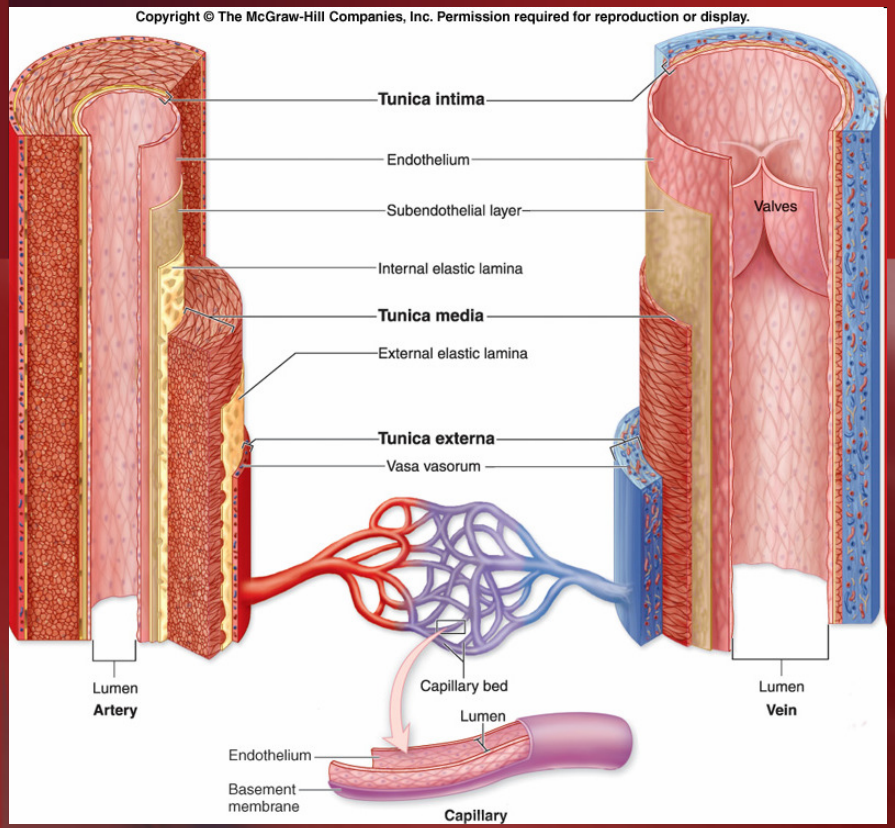

- Žily = venae
  - Tunica intima
    - Endotel - vo vnútri chlopne
  - Tunica media
    - hladká svalovina + kolagén
  - Tunica externa
    - Vasa vasorum – drobné cievy vyživujúce stenu cievy
- Kostrové svaly napomáhajú návratu krvi

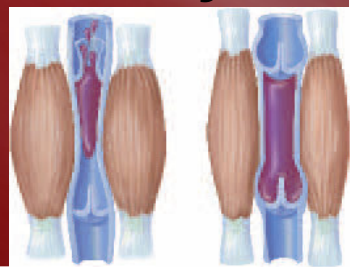

Cievy

- Tepničky = arterioly
  - Endotel
  - Hladká svalovina
    - Výrazne menia svoj priemer, čím ovplyvňujú prekrvenie orgánov
- Vlásočnice = kapiláry
  - Jednovrstvový epitel
    - Styčná plocha medzi krvou a tkanivom
      - presun látok do / z tkanivového moku (interstícium)

Obehová sústava

- Pľúcny (malý) krvný obeh
  - Truncus pulmonalis
    - A. pulmonalis dextra
    - A. pulmonalis sinistra
  - Vv. pulmonales (2 páry)

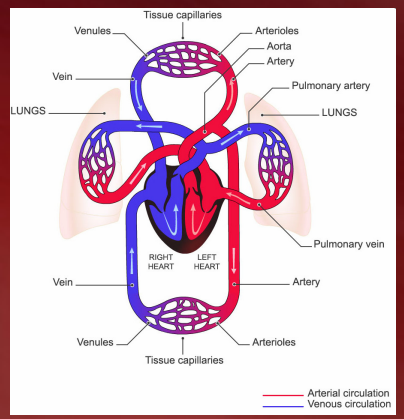

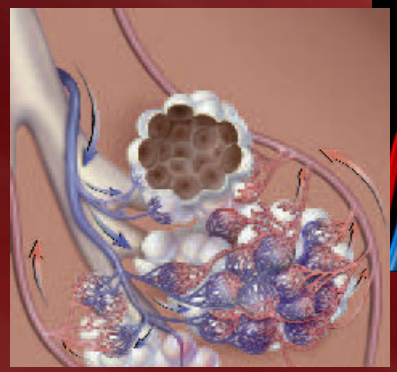

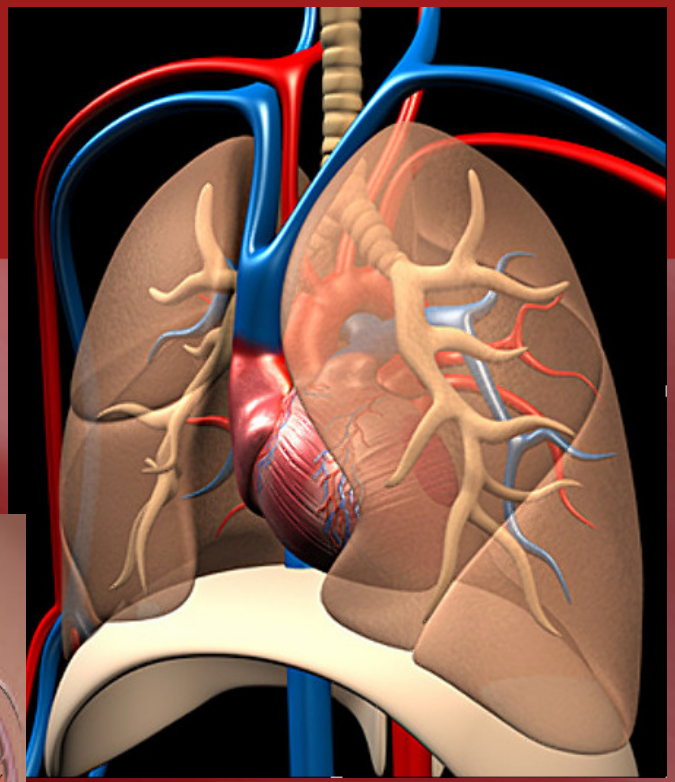

Obehová sústava

- Telový (veľký) krvný obeh – tepnová časť
  - Aorta
    - arteria coronaria sinistra et dextra – koronárny obeh srdca
    - truncus brachiocephalicus
      - a. carotis comunis dextra
      - a. subclavia dextra – p. ruka
    - a. carotis comunis sinistra
    - a. subclavia sinistra – ľ. ruka

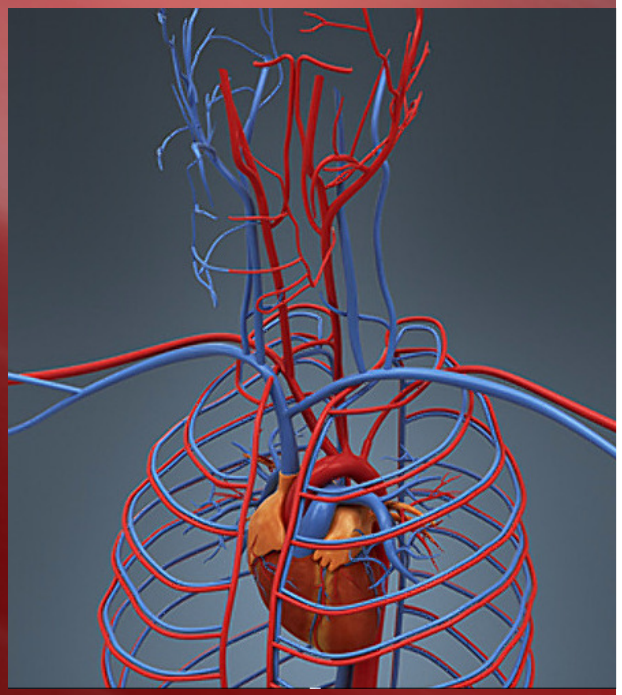

Obehová sústava

- Telový (veľký) krvný obeh – tepnová časť
  - Aorta thoracica
    - arteriae intercostales
  - Aorta abdominalis
    - arteria gastrica → žalúdok
    - a. hepatica → pečeň
    - a. renalis sinistra et dextra → obličky
    - a. mesenterica superior → črevá
    - a. mesenterica inferior → črevá
    - a. illiaca communis sinistra et dextra → ľ. a p. noha
    - a. testiculares sinistra et dextra ♂; a. ovarica sin. et dex. ♀

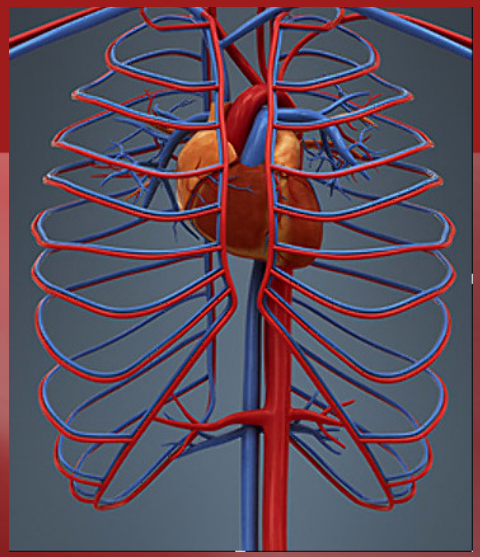

Obehová sústava

- Telový (veľký) krvný obeh – žilová časť
  - V. cava superior
    - v. brachiocephalica sin. et dex.
      - v. jugularis externa sin. et dex.
      - v. jugularis interna sin. et dex.
      - v. subclavia sin. et dex.
    - vv. intercostales
  - V. cava inferior
    - hrudníkový úsek
      - vv. intercostales
    - brušný úsek
      - vv. hepaticae
      - vv. renales
      - vv. testiculares ♂; vv. ovaricae ♀
      - v. mesenterica – absorbuje živiny z čriev
        - » v. portae – funkčný obeh pečene
      - v. iliaca

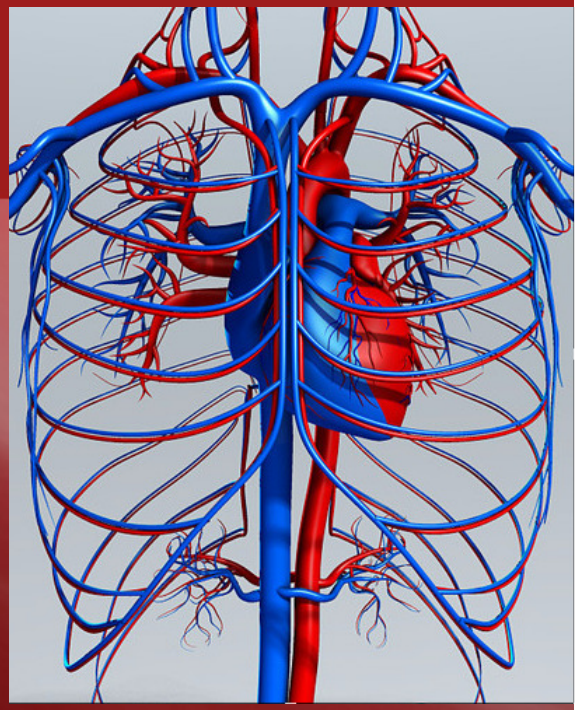

Obehová sústava – horná konč.

- arteria subclavia (1)
  - arteria axillaris (2)
  - a. brachialis (3)
    - a. radialis – palec (4)
    - a. ulnaris – prsty a dlaň (5)

- vena subclavia (1)
  - v. axillaris (2)
  - v. brachialis (3)
    - v. mediana (6)
  - v. cephalica (7)

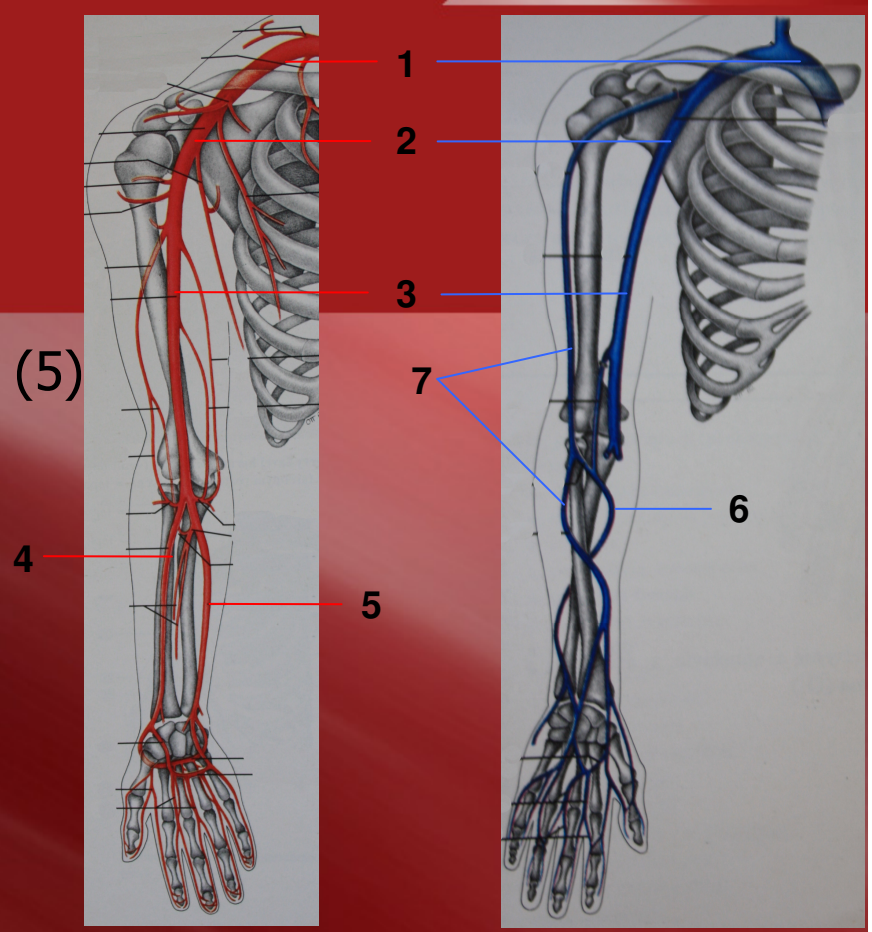

Obehová sústava – dolná konč.

- arteria illiaca communis
  - a. iliaca interna
  - a. iliaca externa
  - a. femoralis (1)
    - a. profunda femoris (2)
      - a. circumflexa femoris (3)
    - a. genus superior (4)
    - a. genus inferior (5)
    - a. tibialis anterior (6)
      - a. dorsalis pedis (7)
    - a. tibialis posterior (8)
      - a. fibularis (9)
      - a. plantaris (10)
- vena iliaca externa (11)
  - v. femoralis (1)
    - v. saphena parva (8)
  - v. saphena magna (12)
  - arcus venosus dorsalis pedis (13)

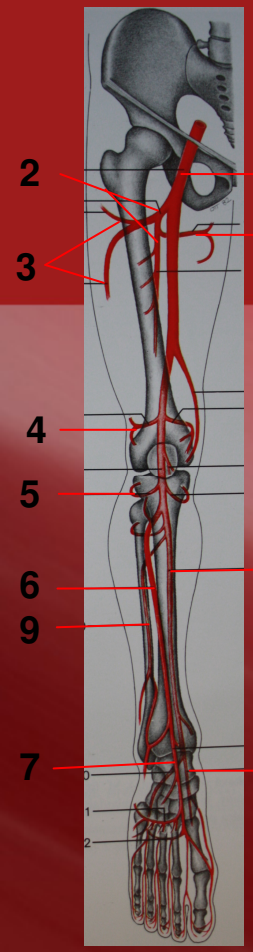

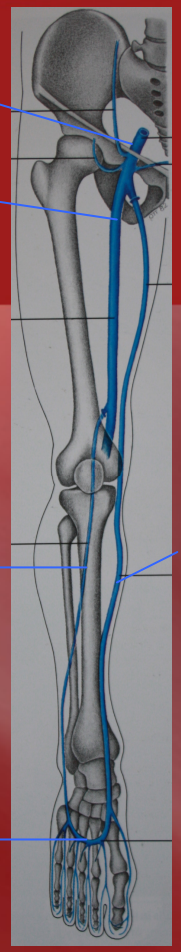

Lymfatická sústava

- lymfatické cievy
  - truncus lymphaticus
- nodi lymphatici
  - cisterna chyli
- slezina – lien
- thymus

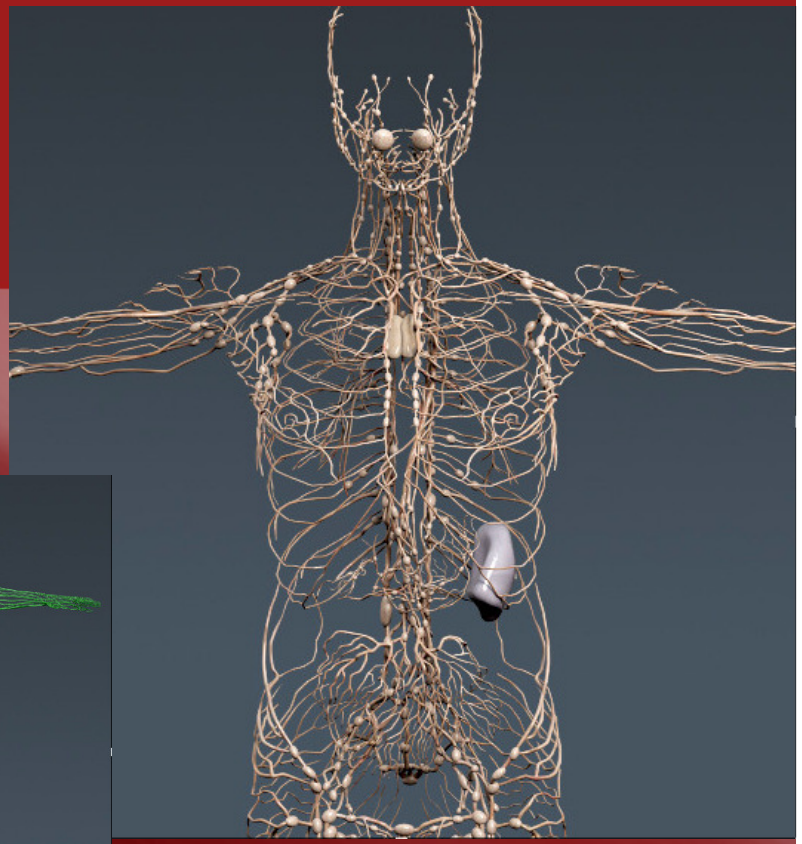

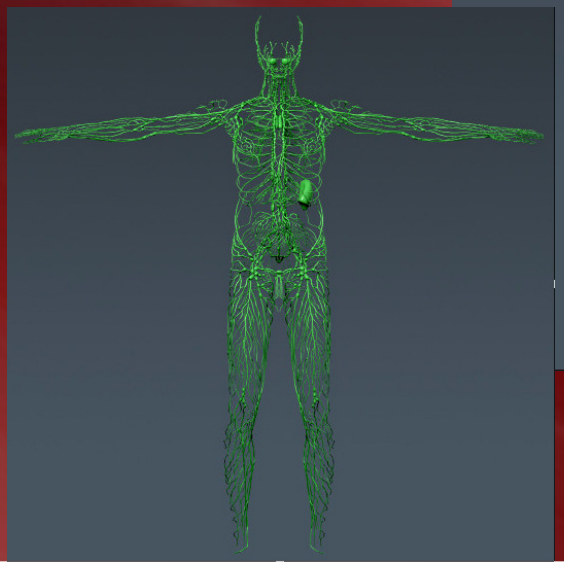

Fetálny krvný obeh

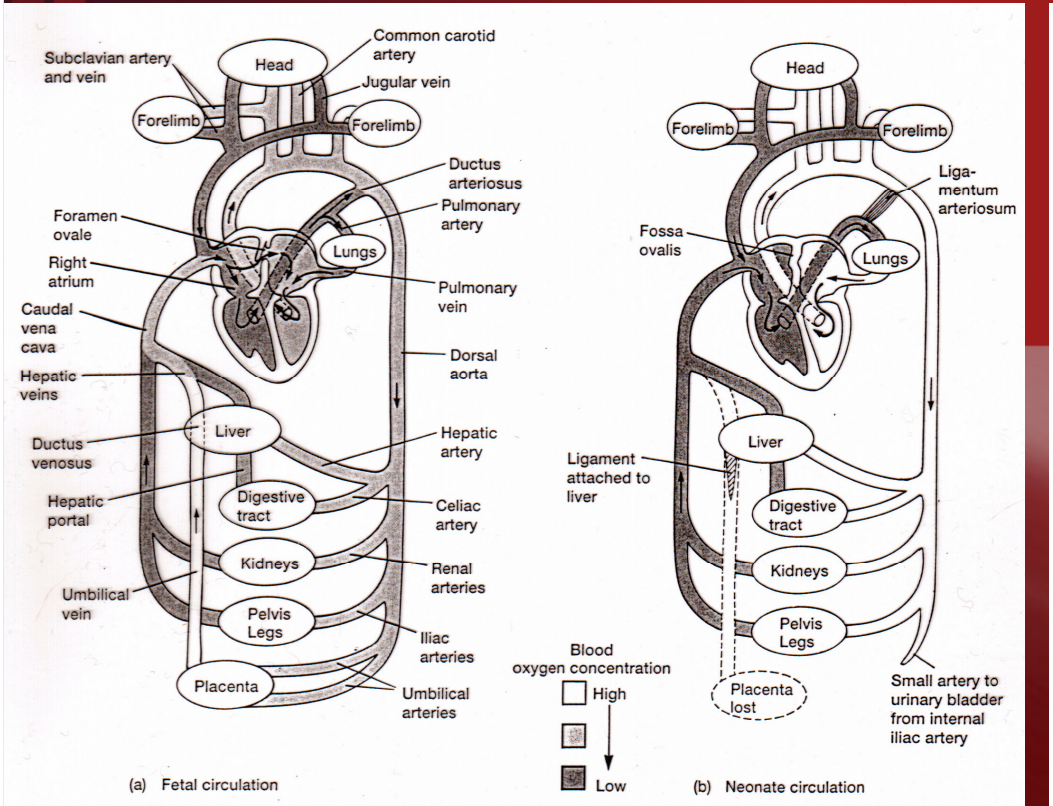

FIGURE 12.42 **Mammalian circulatory changes at birth.** (a) Fetal circulation. Because the lungs are nonfunctional, uptake of oxygen and nutrients occurs through the placenta. The ductus venosus is a liver bypass. The foramen ovale and ductus arteriosus are lung bypasses. (b) Neonatal circulation. Following birth, the lungs become functional, the placenta departs, and the ductus venosus, foramen ovale, and ductus arteriosus close.
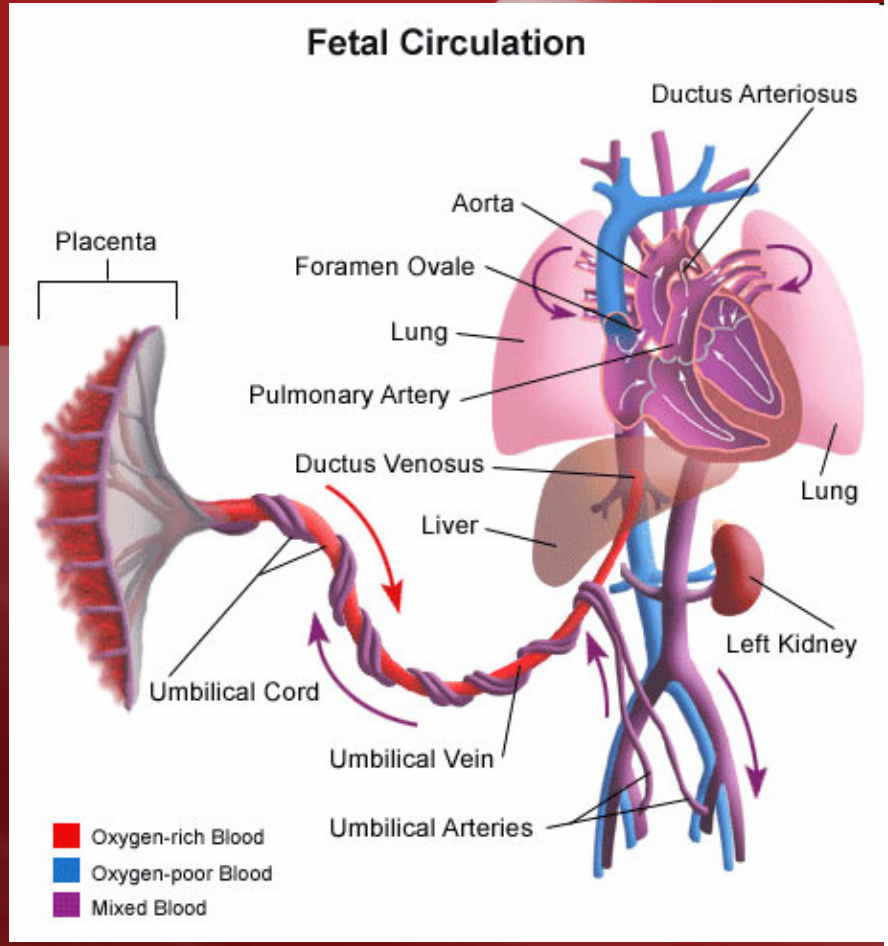
After Walker.